

Sympathetic Neurolysis in Management of Cancer-related Visceral Pain

Dr. LEUNG Yin-ye

Associate Consultant, Princess Margaret Hospital

Introduction

Pain is one of the most feared consequences of cancer. In 1986, the World Health Organization proposed a “three-step analgesic ladder” to guide medication treatment for cancer pain. However, even when these guidelines are followed, up to 10 to 20% of cancer patients still report inadequate analgesia (1). In these patients interventional approach is required to improve their pain control.

Cancer-related pain can arise from the irritation of somatic tissues, viscera, or nervous structures. For pain originating from the viscera, chemical neurolysis of the sympathetic nervous system may be appropriate.

Visceral Afferent Innervation

Vagus nerve innervates organs in the thoracic and abdominal cavities, whereas spinal visceral nerves innervate the same thoracic and abdominal organs, as well as those in the pelvic floor.

Most spinal visceral afferent nerves pass through the sympathetic pre- and para-vertebral ganglia on their way back to the spinal cord. Therefore, sympathetic chain at the appropriate level can be targeted and blocked to treat cancer pain arising from the visceral organs.

Chemical Neurolysis

Neurolysis is performed in almost all of the sympathetic blocks as catheter placement is difficult and can be impractical. The most common agents used for disrupting the neural pathways are alcohol and phenol.

Alcohol is hypobaric in relation to CSF. It spreads rapidly from the injection site and can cause intense pain when injected. It is necessary to precede the alcohol block with a local anesthetic to decrease the associated pain. Although the minimum effective concentration of alcohol for neurolysis has not been established, most specialists use a concentration ranging from 50% to 98%. The degree of neural blockade increases over the first several days following neurolysis with alcohol.

On the other hand, phenol has a local anesthetic effect and is not painful when injected. It is more viscous than alcohol and is hyperbaric in CSF. Phenol is available at a maximum concentration of 6.7% when prepared in water, but can be concentrated to 15% when mixed with glycerol or

radiopaque contrast. The degree of neural blockade following injection of phenol is maximal in the first hours after injection and tends to subside somewhat thereafter. Phenol seems to have a shorter duration of clinical action compared with alcohol.

Coeliac Plexus Block

Indication

The celiac plexus carries afferent fibers from stomach to mid transverse colon including pancreas, and neurolytic blockade can be used to treat cancer related visceral pain originating in the upper abdomen. Deep visceral pain related to pancreatic cancer is typical indication for celiac plexus block.

One should note that pain originating from the somatic nerve fibers coming from the upper abdominal wall will not be blocked by celiac plexus neurolysis. Therefore it is important to distinguish between visceral versus somatic pain before contemplating this procedure.

Anatomy

Celiac plexus is a complex grouping of 1 to 5 ganglia of various sizes interconnected by a dense network of neural fibers and is located in the upper abdomen typically anterolateral to the aorta at the L1 vertebral level, just caudal to the take-off of the celiac artery.

It is formed by the convergence of sympathetic preganglionic and afferent fibers from the greater (T5-T10), lesser (T10-T11), and least (T12) splanchnic nerves. Parasympathetic preganglionic and afferent fibers originating from the vagus nerves also contribute to the celiac plexus.

Technique

Classically, the celiac plexus is blocked using the posterior percutaneous approach. If the patient cannot tolerate the prone position, an anterior approach can be used, but this involves passage of the needle through the abdominal visceral with potential complications e.g. peritonitis and intra-abdominal abscess.

Several types of imaging can be used to facilitate percutaneous celiac plexus block: fluoroscopy, endoscopic or percutaneous ultrasound, and even computed tomography (CT) guided.

For the posterior percutaneous approach to the celiac plexus, the transcrural or anterocrural, retrocrural and splanchnic nerve block techniques have been described. The difference in each of these techniques lies on the final location of the needles.

For coeliac plexus block using a transcrual approach, the local anesthetic or neurolytic solution is placed directly on the celiac ganglion anterolateral to the aorta. The needles pass directly through the crura of the diaphragm en route to the celiac plexus. Spread of the solution towards the posterior surface of the aorta may thus be limited, perhaps reducing the chance of spinal nerve or spinal segmental artery involvement.

In the retrocrual approach, the needles remain posterior to the diaphragmatic crura, thus avoiding the risk of penetrating the aorta. A smaller volume of solution can be used, and the success is unlikely to be affected by anatomic distortion caused by extensive adenopathy or tumor within the pancreas.

Splanchnic nerve block is a minor modification of the classic retrocrual technique. The only difference being that for splanchnic nerve block, the needles are placed over the midportion of the T12 vertebral body rather than over the superior aspect of L1 vertebral body (Fig 1 & 2). Apart from that, they are essentially the same technique, relying on cephalad spread of solution to block the splanchnic nerves in a retrocrual location.

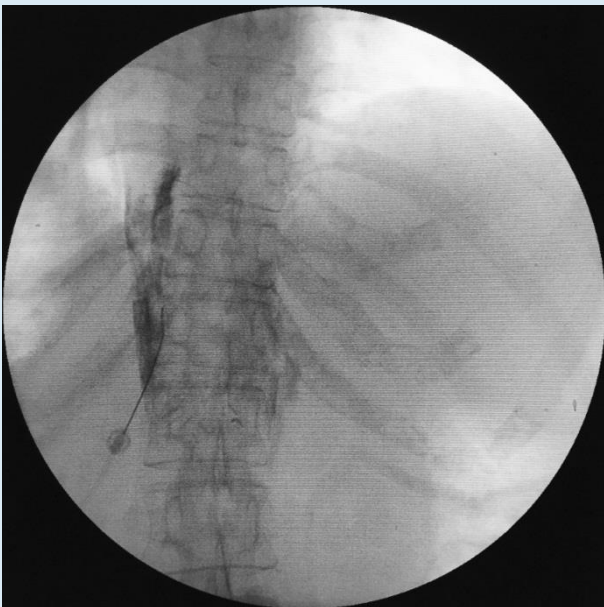


Fig 1. Anteroposterior fluoroscopic view of final needle placement for splanchnic nerve block approach to the celiac plexus

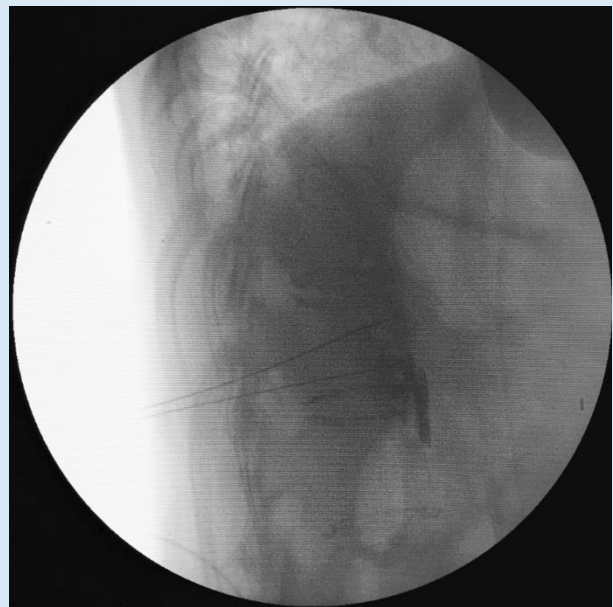


Fig 2. Lateral fluoroscopic view of final needle placement for splanchnic nerve block approach to the celiac plexus

It is unclear which percutaneous technique produces the best result and there is little compelling data to support one technique over another.

A 1992 study by Ischia et al. (2) compared the outcomes of the transcrual transaortic approach, the retrocrual technique, and neurolysis of the splanchnic nerves at the T12 level. No statistically significant differences ($p>0.05$) in analgesia were found among the three techniques.

On the other hand, in the study of Özyalçın et al. (3), pain scores and codeine use decreased more after bilateral posterior splanchnic nerve destruction than after a transaortic coeliac plexus neurolysis in patients with body and tail located pancreatic cancer. Local invasion of the tumor may be responsible for the difference in effect because the spread of the neurolytic agent may be inadequate with the transcrural approach.

Evidence of Efficacy

Among the sympathetic nerve blocks, celiac plexus block is the one most well studied.

In addition to multiple case series and case reports (4) showing the efficacy of coeliac plexus neurolysis in the management of upper abdominal cancer pain, there are several randomized controlled trials comparing the efficacy of celiac plexus block to systemic analgesic therapy. Among them, the one done by Wong and his colleagues in the Mayo Clinic is the most well-designed study (5). In Wong's study, 100 patients were randomly assigned to receive either neurolytic coeliac plexus block or systemic analgesic therapy alone with a sham injection. All patients could receive additional opioids managed by a clinician blinded to the treatment assignment. The major finding of the study was that coeliac plexus block significantly improved pain relief in patients with pancreatic cancer compared with optimized systemic analgesic therapy alone. However, opioid consumption, frequency of opioid adverse effects and quality of life were not significantly different between groups.

In 2011, the Cochrane Library Review examined the available evidence for use of coeliac plexus block for pancreatic cancer pain in adults (6). A few years later, another meta-analysis by Zhong et al. identified and compared seven randomized control trials of pain relief for pancreatic cancer, by treatment with medical management alone to celiac plexus blockade with medical management (7). Basically, both of them showed similar results. For the effects in pain score, the coeliac plexus block group had a significantly lower pain score at 4 weeks, but the significance was not maintained at 8 weeks. For opioid consumption, patients treated with coeliac plexus block required less opioid at all time points compared with those treated with systemic analgesic therapy alone. This may indicate that the pain of coeliac plexus block treated group was actually less severe, although interestingly the pain scores were no longer significantly different.

In conclusion, there are good evidence that coeliac plexus block improves pain relief for patients with pancreatic cancer.

Complications

Because celiac plexus neurolysis results in sympathetic blockade of the upper abdomen, transient postural hypotension and diarrhoea is common after the procedure. Other rare but serious complications include pneumothorax, retroperitoneal haematoma and paraplegia due to acute ischemic myelopathy (probable involvement of the artery of Adamkiewicz). Spread of neurolytic solution posteriorly can sometimes affect the lower thoracic and lumbar somatic nerves, which can potentially result in radicular pain.

Superior Hypogastric Plexus Block

The superior hypogastric plexus is a lower continuation of the inferior mesenteric plexus that contains postganglionic sympathetic and afferent visceral pain nerve fibers. The plexus covers a wide area spanning the ventral-lower lumbar vertebrae, with most fibers found at the L5-S1 junction. Nearby structures include the bifurcation of the aorta into the common iliac vessels.

The primary indication for the superior hypogastric plexus block is visceral-type pain arising from the pelvic organs.

Similar to the celiac plexus block, the superior hypogastric plexus can be approached posteriorly as well as anteriorly. Besides the classic posterior lateral approach for blockade introduced by Plancarte in 1990 (8), the transdiscal approach to the superior hypogastric plexus has also been described. In 2006, Gamal conducted a prospective, randomized trial comparing the classic approach to blockade of the superior hypogastric plexus with the transdiscal technique (9). Both groups showed significant reductions in pain scores and daily morphine consumption. It was concluded that the superior hypogastric plexus block through the transdiscal approach was as equally effective as the classic approach, with no noted complications.

The superior hypogastric plexus block is less well studied than the celiac plexus block. No randomized studies have been published, but several prospective case series have consistently demonstrated good pain relief and reduced opioid consumption in patients with visceral-type pelvic pain.

Potential complications of superior hypogastric plexus block may include bleeding, bruising, infection, local anesthetic toxicity, damage/irritation to nerve structures, sexual dysfunction, intraperitoneal and intramuscular injection, and visceral injury.

Ganglion Impar Block

The ganglion impar is the inferior, distal termination of the paired sympathetic chains. In addition to post-ganglionic sympathetic nerve fibers, it also contains pain afferent nerve fibers. It is typically located on the ventral aspect of the sacrococcygeal junction, although it can be located distally, ventral to the coccyx itself.

The indication for performing the ganglion impar block includes refractory visceral pelvic/perineal pain arising from cancers of the pelvic organs.

The ganglion impar block can be performed using the trans-anococcygeal or trans-sacrococcygeal approaches. For the transanococcygeal technique, a curved-needle is directed cephalad through the anococcygeal ligament to the ventral aspect of the sacrococcygeal junction where the ganglion impar is located. To prevent accidental perforation of the rectum by the needle, the operator needs to perform a continuous rectal examination. For the trans-sacrococcygeal approach, the needle is

advanced through the cleft of the sacrococcygeal junction until the needle tip lies anterior to the ventral sacrococcygeal ligament (Fig 3 & 4). This technique is easier to perform and more comfortable for the patient. Positioning of the needle may be guided by fluoroscopy or ultrasound.

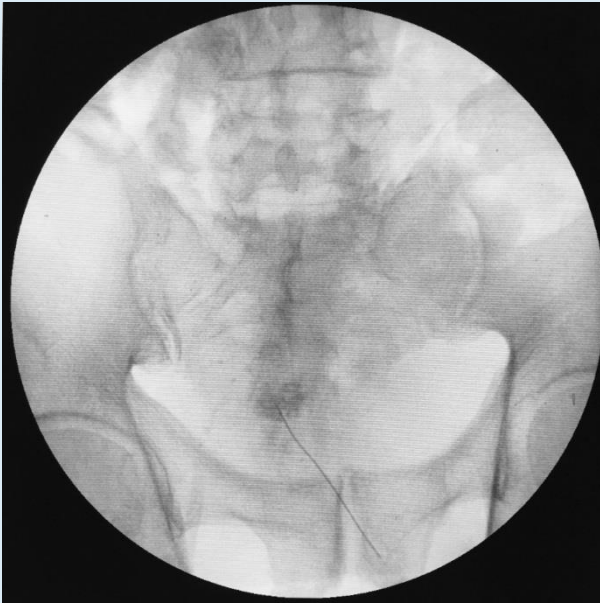


Fig 3. Anteroposterior fluoroscopic view of final needle placement for trans-sacrococcygeal approach to the ganglion impar

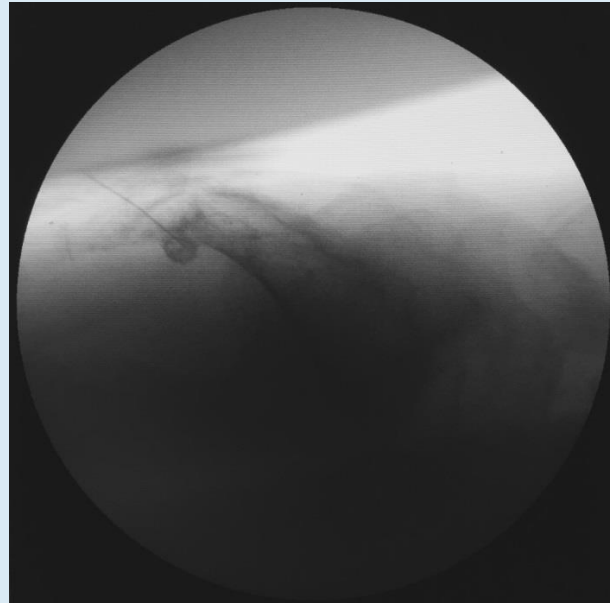


Fig 4. Lateral fluoroscopic view of final needle placement for trans-sacrococcygeal approach to the ganglion impar

High quality evidence for the use of ganglion impar blocks for the treatment of refractory cancer-related visceral pelvic/perineal pain does not currently exist as the few articles available are either case reports or small case series that demonstrate efficacy (10).

Apart from bleeding, bruising, infection and local anesthetic toxicity, sacral nerve roots injury and rectal perforation is potential complications due to the the proximity of the ganglion impar to these structures.

References

- (1) Tay W, Ho KY. The role of interventional therapies in cancer pain management. *Ann Acad Med Singapore*. 2009 Nov;38(11):989-97.
- (2) Ischia S, Ischia A, Polati E, et al. 3 posterior percutaneous celiac plexus block techniques—A prospective, randomized study in 61 patients with pancreatic-cancer pain. *Anesthesiology* 1992;76: 534–40.
- (3) Özyalçın NS, Talu GK, Camlica H, et al. Efficacy of coeliac plexus and splanchnic nerve blockades in body and tail located pancreatic cancer pain. *Eur J Pain* 2004;8:539–45.
- (4) Nagels W, Pease N, Bekkering G, et al. Celiac plexus neurolysis for abdominal cancer pain: a systematic review. *Pain Med*. 2013 Aug;14(8):1140-63.

- (5) Wong G, Schroeder D, Carns P, et al. Effect of neurolytic celiac plexus block on pain relief, quality of life, and survival in patients with unresectable pancreatic cancer: A randomized controlled trial. *JAMA* 2004; 291:1092–9.
- (6) Arcidiacono PG, Calori G, Carrara S et al. Celiac plexus block for pancreatic cancer pain in adults. *Cochrane Database Syst Rev*. 2011 Mar 16;(3):CD007519.
- (7) Zhong W, Yu Z, Zeng JX, et al. Celiac plexus block for treatment of pain associated with pancreatic cancer: a meta-analysis. *Pain Pract*. 2014 Jan;14(1):43-51.
- (8) Plancarte R, Amescua C, Patt R, Aldrete A. Superior hypogastric plexus block for pelvic cancer pain. *Anesthesiol-ogy*. 1990;73:236–239.
- (9) Gamal G, Helaly M, Labib Y. Superior hypogastric block: transdiscal versus classic posterior approach in pelvic cancer pain. *Clin J Pain*. 2006;22:544–547.
- (10) Day M. Sympathetic blocks: the evidence. *Pain Pract*. 2008 Mar-Apr;8(2):98-109.